

An unusual trichobezoar in a non-psychiatric nine-year-old girl

Abdol-Hassan Talaiezhadeh¹, Hazhir Javaherizadeh²

¹Imam Khomeini Hospital, Ahvaz Jundishapur University of Medical Sciences, Ahvaz, Iran

²Arvand International Division, Ahvaz Jundishapur University of Medical Sciences, Ahvaz, Iran

Przełąd Gastroenterologiczny 2011; 6 (6): 409–410

DOI: 10.5114/pg.2011.25997

Key words: trichobezoar, vomiting, weight loss, foreign bodies, bezoars.

Address for correspondence: Hazhir Javaherizadeh MD, Arvand International Division, Ahvaz Jundishapur University of Medical Sciences, Iran, phone/fax: +98 631 3332005, e-mail: Hazhirja@yahoo.com

Abstract

Bezoars are rare foreign body masses or concretions formed in the stomach and small bowel, which are found in less than 0.5% of patients undergoing upper gastrointestinal endoscopies. We report a 9-year-old female without psychiatric history who was subjected to an exploratory laparotomy due to a large abdominal mass and food intolerance. A gastrotomy was performed and a 25 cm × 15 cm trichobezoar was extracted.

Introduction

A foreign body in the gastrointestinal tract may lead to abdominal pain, halitosis, obstruction, or perforation [1]. Bezoars are foreign bodies that are said to accumulate slowly in the gastrointestinal tract, especially in the stomach [2, 3]. The overall prevalence of bezoars is less than 0.5% of upper digestive tract endoscopy [4]. Trichobezoars make up 55% of all bezoars [5] and 90% of all trichobezoars occur in female cases [6]. Bezoar formation in a healthy person is rare and typically is seen in young women who have psychiatric disorders [7].

Case report

A 9-year-old girl was referred to the surgery ward in Ahvaz Apadana hospital for evaluation following a history of vomiting, persistent weight loss and stomach fullness over the past 5 months. She had no history of psychiatric disorders. Endoscopy of the upper digestive tract revealed a blackened mobile mass blocking passage of the endoscope. In addition, the computed tomography (CT) showed a hypodense circular 25 cm × 15 cm mass including gas bubbles in the stomach (Figure 1).

Surgical treatment was initiated by general anaesthesia, which was done due to the finding of a large intragastric mass in the form of the stomach. Gastrotomy was performed and a trichobezoar composed of strands of hair was removed (Figure 2). The patient pro-

gressed with no complications and was discharged from hospital 3 days after surgery.

Discussion

The literature previously confirmed that most bezoars occur in young women with psychiatric disorders [7]. Ali *et al.* reported two cases of Rapunzel syndrome, with and without psychiatric disorder [8]. The patient in this report had no psychiatric disorder. The diagnosis is usually made by upper digestive tract endoscopy and confirmed by computed tomography, but in cases in which the endoscopic passage is blocked, such as the present case, physical examination associated with computed tomography is helpful. One option for treatment and management of trichobezoars is to try to dissolve the materials, but the type of surgery is dependent on the size of the mass. A small trichobezoar may be removed by endoscopy. However, in the case of large masses, this method is less likely to be successful. Thus, in such cases the stomach cavity had to be opened and gastrostomy performed, as has been described in the literature [9, 10].

In conclusion, because of the rarity of gastrointestinal tumours in children and adolescents, in the case of dealing with an abdominal mass in young patients, usually Rapunzel syndrome should be taken into consideration in the investigation of cases with history of vomit-

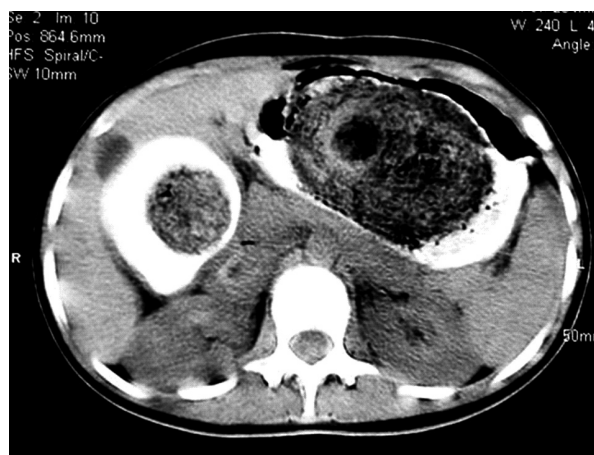


Fig. 1. Computed tomography image of a trichobezoar in the stomach

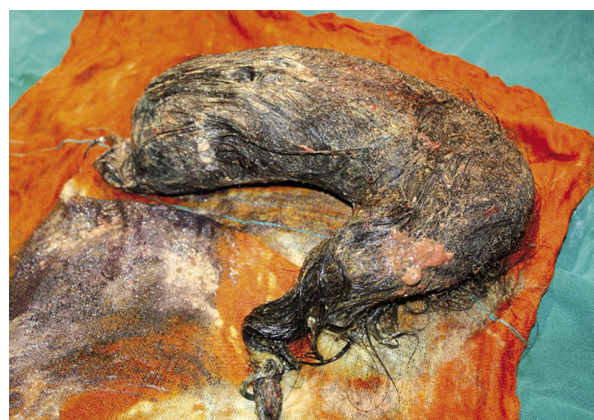

Fig. 2. Trichobezoar in the shape of stomach removed at surgery

ing, persistent weight loss and anaemia. Also, we must keep in mind the possibility of foreign bodies if there is unusual presentation of gastrointestinal problems. Diagnosis and treatment should include endoscopy with computed tomography and surgical management in most cases.

References

- Ghoroubi J, Imanzadeh F, Sayyari AA, et al. Foreign body impacted in jejunum. *Ann Pediatr Surg* 2010; 6: 39-40.
- Tayyem R, Ilyas I, Smith I, et al. Rapunzel syndrome and gastric perforation. *Ann R Coll Surg Engl* 2010; 92: W27-8.
- Nair MS, Nair BM. A rare presentation of Rapunzel syndrome manifesting in the immediate post-appendectomy period. *The Internet Journal of Surgery* 2008; 14: 2.
- Yau KK, Siu WT, Law BK, et al. Laparoscopic approach compared with conventional open approach for bezoar-induced small-bowel obstruction. *Arch Surg* 2005; 140: 972-5.
- Sharma V. Gastrointestinal bezoars. *J Indian Med Assoc* 1991; 9: 338-9.
- Bholla SS, Gurjit S. Trichobezoar. *J Indian Med Assoc* 1993; 91: 100-1.
- Ersoy YE, Ayan F, Ayan F, et al. Gastro-intestinal bezoars: thirty-five years experience. *Acta Chir Belg* 2009; 109: 198-203.
- Ali AM, Hasaab MH. Rapunzel syndrome: an uncommon problem in children. *Ann Pediatr Surg* 2007; 3: 167-9.
- Gorter RR, Kneepkens CM, Mattens EC, et al. Management of trichobezoar: case report and literature review. *Pediatr Surg Int* 2010; 26: 457-63.
- Cintolo J, Telem DA, Divino CM, et al. Laparoscopic removal of a large gastric trichobezoar in a 4-year-old girl. *JLS* 2009; 13: 608-11.